

DRY EYE

Case reviews in dry eye management

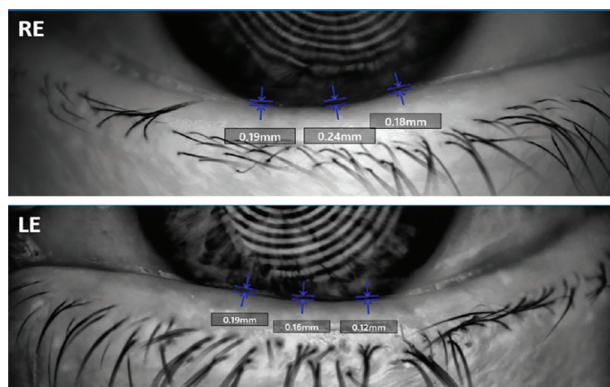
In a series of case studies from her Somerset practice, Therapeutic optometrist Sarah Farrant discusses using the new Topcon MYAH for the management of a dry eye patient.

Effective management of dry eye disease is now an integral part of my day-to-day role in my specialist clinics. The demand has increased year on year and has shown little sign of slowing down during the Covid-19 pandemic. In fact, with mask associated dry eye (more commonly described as MADE) now a newly recognised acute dry eye problem, the need for maintenance of a good quality tear film is more important than ever. While the prevalence of dry eye disease is increasing in the population, the age of onset is decreasing, and modern lifestyles likely create an increased burden on the ocular surface. In light of this, the next highly anticipated TFOS DEWS report will be titled *A Lifestyle Epidemic*. In this context, optometrists are perfectly poised to effectively manage these cases in primary care.

Up until recently, my diagnostic work up consisted primarily of subjective measurements using grading scales and experience, my TearLab for osmolarity measurement and utilising my slit lamp anterior camera to both document and educate patients regarding the current status of their disease. Lately, I have been using dedicated diagnostic devices in my clinical practice. These have not only added more quantitative parameters, but also improved the clinic workflow. My approach is generally based on the tear film and ocular surface society (TFOS) DEWS II report both as a diagnostic guide and a basis for an evidence-based management algorithm.

In this article, I will present a recent case seen in my dry eye clinic which makes use of a new diagnostic methodology; namely, the MYAH (UK distributor, Topcon Medical Limited).

FIGURE 2 Tear meniscus height of both eyes measured with the MYAH



FIRST PRESENTATION AND INITIAL DIAGNOSIS

Good history taking can reveal so much about the potential triggers, exacerbating risk factors and even the likely type of dry eye. A good synopsis can be found in the TFOS DEWS II report online.¹

CW, female, 73 years old, presented as a new patient to my acute emergency clinic, with a symptomatic, sore and red left eye which she had been treating with chloramphenicol for a week to no avail.

At this point, I diagnosed a left marginal keratitis secondary to significant blepharitis and treated her with Maxitrol (neomycin,

FIGURE 1 NITBUT (non-invasive tear break up time) of both eyes as displayed on the MYAH

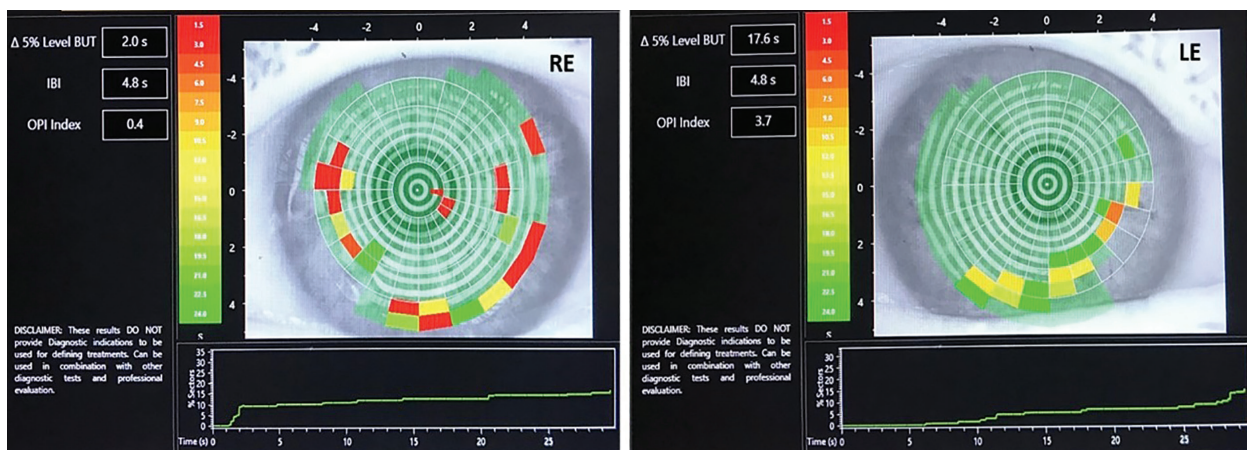
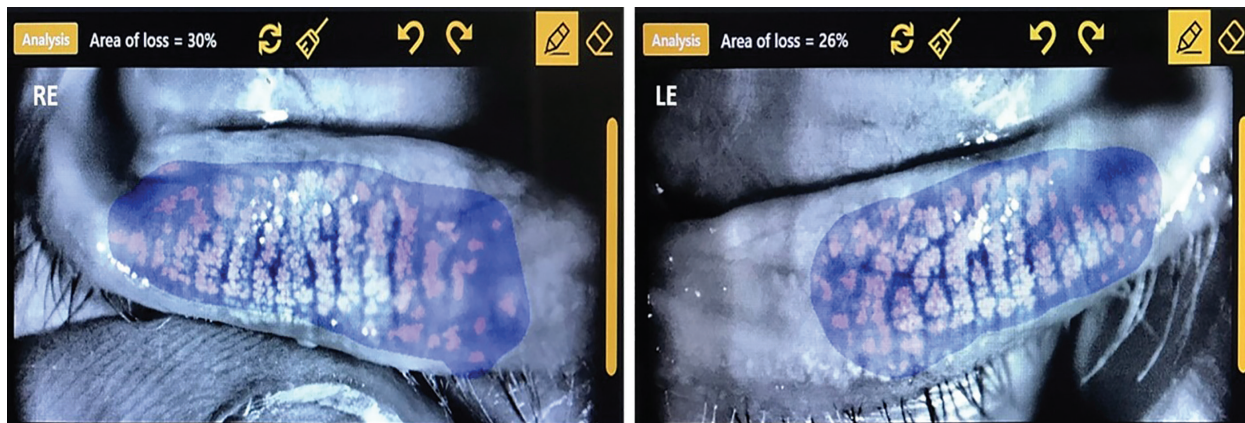


FIGURE 3 Meibography of the inferior eyelids of both eyes using the MYAH



polymyxin B, and dexamethasone eye drops). These were to be used qds 2/52, with a taper to bd 2/52 followed by a two-week review.

Outcome of initial treatment

CW returned two weeks later, much improved and happy. At this stage, I discussed with her the reason for the keratitis and the need for effective management of her ocular surface disease, so recommended she attend our ‘Dry and Watery Eye’ dedicated clinic. An appointment was made for one week later and, in the meantime, I advised her to use Hyabak topical lubricant; qds LE (± RE).

DRY AND WATERY EYE CLINIC APPOINTMENT

Her history included ocular surface concerns ever since

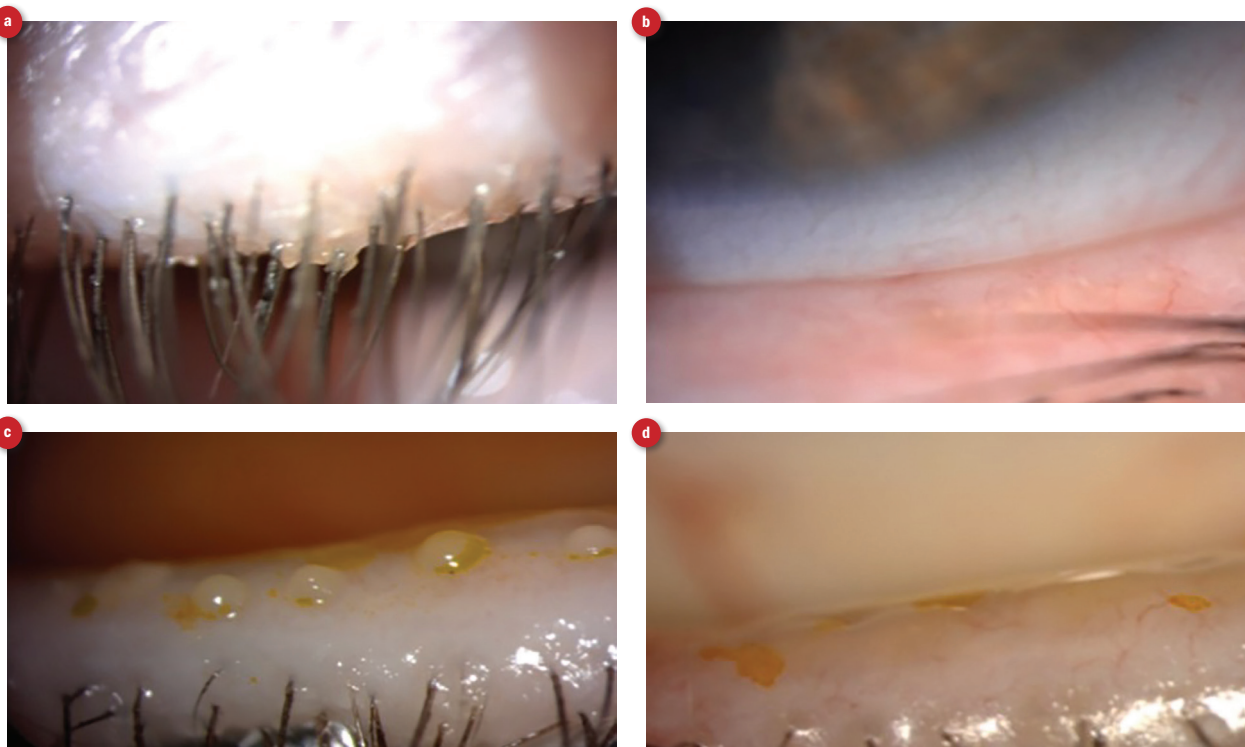
undergoing bilateral macular hole and cataract surgery in both eyes about 15 years ago. She has suffered gradually increasing symptoms of sore gritty episodes and increasingly red eyes.

Clinical findings

- General health;
 - Diabetes type II, under diet control
- Medications;
 - Statin
 - ACE inhibitor
 - Alpha-blocker
- Patient questionnaire;
 - DEQ-5 score; 16 (the DEQ-5 scoring system dictates that a score over six indicates dry eye)

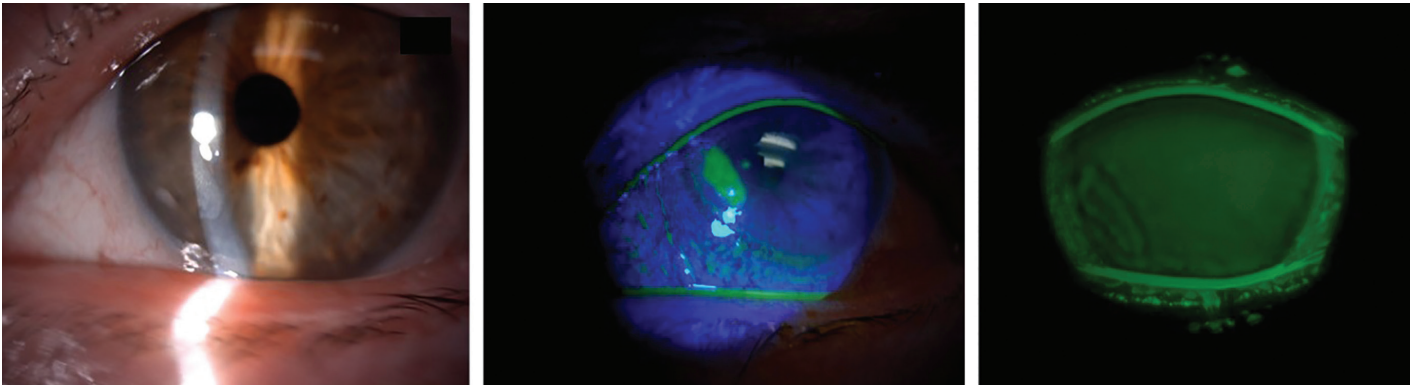


FIGURE 4 Slit lamp images. a: cylindrical collarettes in the upper eyelashes; b: telangiectasia at the lid margins (grade 4) and subtle LIPCOF; c: lower eyelid meibomian glands orifices after the first expression (grade 3); d lower eyelid Meibomian glands orifices after two months of at home treatment (grade 1). Images taken with a Topcon SLD701 and D4 camera



DRY EYE

FIGURE 5 Slit lamp images showing a: corneal scar with white slit lamp; b: fluorescein stain during active marginal keratitis episode; c: after resolution showing negative stain over the inactive scar. Images taken with a Topcon SLD701 and D4 camera



Before assessing tear and blink integrity, it was recorded that the patient was using Hyabak (qds) (not an approved product in Australia) and Maxitrol (not an approved product in Australia) and that the most recent drop instillation was four hours ago. The next measurements were taken using the MYAH.

- Non-Invasive Tear Break Up Time (NITBUT); this is a crucial element for an effective tear surface analysis. Understanding the current stability of the tears helps to predict the likely effect on the ocular surface, as well as other aspects such as vision fluctuations. Normal is generally considered to be above 10 seconds, but this can vary according to the analysis method used;
 - R; 2 seconds (s)
 - L; 17.6 s
- Inter Blink Interval (IBI)
 - R; 4.8 s
 - L; 4.8 s
- Ocular Protection Index (OPI)
 - R; 0.4
 - L; 3.7

It is worth noting here that the tear break-up time (TBUT) alone does not give you the full picture. To understand the dynamics of the TBUT effect on the eye, you must also measure the habitual blinking state of the patient, measured here as the inter-blink interval, or IBI.

Once you establish typical blinking rates, you can calculate the OPI score as follows:

$$\text{OPI} = \text{TBUT} / \text{IBI}$$

In effect, this will indicate whether the eye is at risk of focal ocular surface damage. If the OPI <1, the cornea is considered at risk. If the OPI >1, a patient's cornea is presumed to be protected.

The significant difference in NITBUT seen on the MYAH results were explained by the recent use of Maxitrol and Hyabak in the LE only.

The MYAH data implied that the RE is at risk, while the LE is not. However, the patient had already been on a course of Maxitrol (qds) and Hyabak (prn) for the LE for three weeks. This could account for the significant difference in both eyes seen at the first clinic appointment.

- Meniscometry (tear meniscus height or TMH); the tear meniscus gives us a general impression of tear volume and

likelihood of aqueous deficiency. In a healthy eye, the height is approximately 0.2 mm.³ Excessive volume can also indicate excess reflex tearing due to meibomian gland dysfunction (MGD) or the potential for a blocked canaliculi or nasolacrimal duct. If TMH is reviewed after fluorescein instillation, it normally takes four to seven minutes post-instillation to give an accurate measurement;

- R; 0.2 mm
- L; 0.16 mm

- Meibography; this technique is one of the best ways of evaluating the long-term health of the meibomian glands (MGs). Gland drop-out signifies a level of disease where there is irreversible damage and so needs to be treated aggressively. It has been hypothesised that meibography should be used in conjunction with other diagnostic evaluations, such as meibomian gland expression (MGX) using MG forceps, to give you a true picture of overall gland health. The automated functionality on the Meibography assessment on the MYAH allows repeatable accurate percentage loss and the results for CW were;

- R; 30% area gland loss
- L; 26% area gland loss

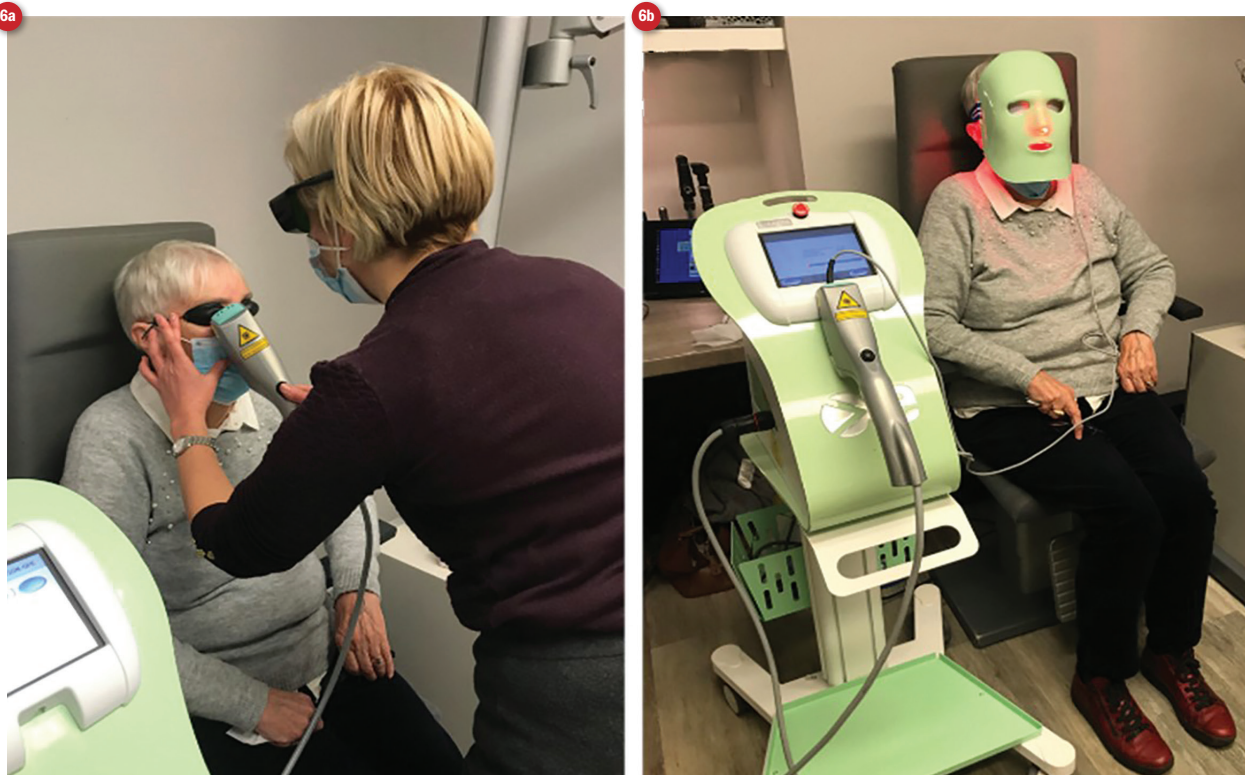Note that, regarding meibography values, when considering more aggressive MGD management options such as intense pulsed light (IPL), it is especially useful to set a baseline for an individual, to optimise treatment and help to avoid further gland loss with careful monitoring.

- Tear osmolarity; the TearLab osmolarity test is a desktop unit for measuring tear osmolarity, one of the key indicators of dry eye disease as per the DEWS II diagnostic methodology.⁵ The normal range should be around 300mOsm/L. Dry eye disease is classified as a measurement above 308mOsm/L. An abnormal reading is also defined when the inter-eye difference is >8mOsm/L, as this can also indicate instability of the tear film. For CW;

- R; 306 mOsm/L
- L; 319 mOsm/L

This result confirmed a dry eye tendency in the left eye given the absolute value being significantly greater than 308 mOsm/L. There was also variability between eyes with a repeatable

FIGURE 6 a: Intense pulsed light (IPL) therapy; **b:** low level light therapy (LLLT). IPL undertaking using the EyeLight system (Espansione, Italy)



osmolarity difference of greater than 8 mOsm/L.

- Slit lamp analysis; I find that a slit lamp work-up is invaluable as an educational tool for my patients. Taking multiple anterior segment images allows me to review, document and educate the patient in a very hands-on way. Slit lamp analysis of CW revealed significant signs of *Demodex blepharitis* (grade 2 of 4 debris around lashes) presenting with the pathognomonic cylindrical collarettes (figure 4a). Marked telangiectasia at the lid margins, crossing and adjacent to the meibomian gland orifices (figure 4b), were a sign of chronic inflammation. Grade 3 lid-parallel conjunctival folds (LIPCOF), with small parallel conjunctival folds adjacent to the lid margin, were noted. These are strongly associated with ocular surface disease. Meibomian gland expression revealed a viscous meibum (graded 3 of 4) which was blocking the glands. (figures 4 c and d).

Old corneal scars were noted in both eyes, likely from recent and previous undiagnosed marginal keratitis episodes (figure 5).

Diagnosis

The patient was diagnosed with *Demodex blepharitis* and meibomian gland dysfunction, with a tendency for recurrent marginal keratitis.

Planning and action

Based on the DEWS II treatment algorithm (and my own experience), the following tailored patient plan was designed;

- Warm compress for 10 mins every day with dedicated pad
- Omega-3 supplements tds
- Systane Complete and Current Drops

- Blephademodex wipes 2/7 to 7/7
- Appointment made for in-practice treatments as follows;
 - Blephex treatment of lid margins
 - Intense pulsed light (IPL); four sessions, 1 month apart (figure 6)

Outcome

After two months of home therapy following the first dry eye clinic appointment, and at the booked IPL session, the viscosity scores for the glands had already improved from three (out of four) pre-treat to two after two months with home therapy (figures 4c and d). Long-term (six-monthly) review, to include regular gland expression, debridement and BlephEx with top up IPLs as required, was the proposed management strategy for the patient. ○

Sarah Farrant is a therapeutic optometrist with a specialist interest in dry eye disease and myopia management practising in Somerset, UK.

REFERENCES

- 1 www.tearfilm.org
- 2 Ousler GW 3rd, Hagberg KW, Schindelar M, Welch D, Abelson MB. The ocular protection index. *Cornea*. 2008;27(5):509–513
- 3 KJ Lim, JH Lee. Measurement of the tear meniscus height using 0.25% fluorescein sodium. *Korean J Ophthalmol*. 1991 Jun;5(1):34-6
- 4 Finis D *et al*. Evaluation of meibomian gland dysfunction and local distribution of meibomian gland atrophy by non-contact infrared meibography. *Current Eye Research*. 2015;40(10):982-9
- 5 Wolffsohn J *et al*. TFOS DEWS II Diagnostic Methodology report. *The Ocular Surface*, 2017, 544e579